

Original Article

Reproductive Toxicity of Ethanolic Extract of *Lecaniodiscus cupanioides* on Male Albino Mice

Adeola Michael Oloyede^{1*}, Chidalu Christabel Anyika¹, Bodunrin Ottu¹

¹Department of Cell Biology and Genetics, University of Lagos, Akoka, Lagos-Nigeria.

Received: 08.04.2020; Accepted: 26.08.2020

Abstract

Background and Aim: *Lecaniodiscus cupanioides* is one of the numerous plants therapeutically used in Southwestern Nigeria for controlling and curing several health complications. In this study, the in vivo effects of the ethanolic extract of *L. cupanioides* on sperm morphology of albino mice were investigated.

Materials and Methods: Fifteen mice (18.2g to 24.8g) were divided into 3 groups of 5 mice. The treatment groups were orally administered 100 and 400mg/kg of the extract, and the control group received distilled water for 49 days. At the expiration of exposure, the mice were sacrificed by jugular puncture. Epididymis and testes were harvested for sperm cytological analysis and testes histology.

Results: Fourteen types of sperm morphological abnormalities observed included: no hook, head with double tails, knobbed hook, amorphous head, bent hook, hook at wrong angle, tail folded over head, pin head, banana-shaped head, tail with no head (prominent), tail with double heads, head with triple tails, wrong tail attachment and head with no tail. Incidence was not significantly different from the control. Furthermore, no correlation between the dose level of the administered drug and incidence of abnormal sperms was observed. Hence, various abnormalities might probably be adduced to natural mistakes during differentiation in spermiogenesis, chromosomal aberration during packaging of genetic material in sperm head, occurrence of small deletions and point mutation during spermatogenesis. Histology of the testes did not show any malformation or alteration, which implies a highly conserved histoarchitecture.

Conclusion: This suggests that the extract might be devoid of any toxic effect on the male reproductive organs and sperms at the doses evaluated within the exposure period.

Keywords: *L. cupanioides*, Sperm, Abnormality, Testes, Toxicity

*Corresponding Author: Adeola Michael Oloyede, Department of Cell Biology and Genetics, University of Lagos, Akoka, Lagos-Nigeria. Email: oloism@yahoo.com.

Please cite this article as: Oloyede AM, Anyika CC, Ottu B. Reproductive Toxicity of Ethanolic Extract of *Lecaniodiscus cupanioides* on Male Albino Mice. *Herb. Med. J.* 2020; 5(1):31-6.

Introduction

Medicinal herbs have been utilized for the treatment and management of various diseases without recourse to dosage in Africa. Most of these plants contain active

substances as secondary metabolites that possess various biological activities which are responsible for their therapeutic reactions (1). However, little or nothing is known about their likely toxicity on the body physiology. The popular use of these herbs is predicated

on the poor economy of Africa, where most orthodox medications are quite beyond the reach of the poor masses. Consequently, many patients prefer to use herbal medicine (1).

Lecaniodiscus cupanioides, a short tropical tree of about 6-12m high, belongs to the sapindaceae family, which is numerously found in Asia and Africa. It is commonly known as aaka or akika, okpu, kafi-namazaki and utantan in Yoruba, Igbo, Hausa and Edo respectively (2; 3). It has been pharmacologically reported to be effective against measles, fever, certain liver diseases, and wounds (4). It is claimed in Southwestern Nigeria that it can control epilepsy and also enhance erection (3). It has also been reported that it possesses analgesic activities (5). In view of the numerous traditional therapeutic uses of this plant for various health maladies, we therefore considered to investigate its toxic potential on the reproductive organs of the male mice in order to examine its effects on the testes and quality of the sperms of the mice.

Materials and Methods

Plant Materials

Leaves of *L. cupanioides* were obtained from Oyingbo market, Lagos State, Nigeria, and authenticated at the Forestry Research Institute of Nigeria (FRIN) Ibadan with Voucher NO. FHI 107345. The research project was approved by the ethical committee of College of Medicine University of Lagos (CMULHREC No. CMUL/ACUREC/01/21/803).

Extract Preparation

The leaves were air-dried and pulverized into coarse powder using a grinder. The dried powder weighing 1943g was soaked in 5200ml of absolute ethanol for 72hours. It was then decanted and sieved using muslin cloth. The filtrate was then transferred to an evaporating dish and was evaporated using a regulated hot plate at a constant temperature of $40\pm 1^\circ\text{C}$. A paste-like extract weighing 35.38g was obtained after evaporation and stored at room temperature in sterile universal bottles.

Experimental Animals

Fifteen male albino mice (*Mus musculus*) with an average weight of 24.2g were obtained from Komad Farm Limited, Abeokuta way, Ogun State, for this experiment. The animals were housed in plastic cages with wood shavings as bedding. They were kept under

room temperature with free access to animal pellet feed and water in each cage. The animals were allowed a week of acclimatization before extract administration and were housed at the Botanical Gardens of the Faculty of Science, University of Lagos.

Study Design

The mice were divided into three groups of five animals. The first and the second groups were administered 100mg/kg, and 400mg/kg respectively. The third group served as the control. They were orally administered the ethanolic extract of *L. cupanioides* daily for seven weeks. The weight of the mice was recorded weekly.

Sperm Head Assay

After receiving daily treatment for a total of 49 days (7 weeks), the assay was carried out according to the procedure explained by Oloyede (6). Briefly, the male mice were sacrificed, and then the epididymis was harvested and excised in a petri-dish containing physiological saline. Clean dry slides were used to prepare smears. They were stained with a mixture of normal saline and Eosin Y dye (9:1) for 45 minutes. The slides were air-dried and investigated under a binocular microscope at X1000 magnification for detecting various abnormalities.

Histology

Testes were processed using microtome RM 2235 and stained with H&E (Hematoxylin and Eosin) for histologic examination under a binocular light microscope.

Statistical Analysis

The data were subjected to sample T-Test in order to examine the statistical significance of the distinction between two means of various parameters between the control and experimental groups. Microsoft Excel T-Test was used to find the P value. P value less than 0.05 was considered significant.

Results and Discussion

Abnormality in sperm morphology differed in the mice with regards to strains and age. Frequency of such an abnormality varied among various inbred of strains. However, it was constant for adult mice, and the incidence ranged from 2-5% (7). Age has been reported to influences the degree and sperm abnormality frequency. The morphological abnormality peculiar to a particular strain would have been achieved by the 13th

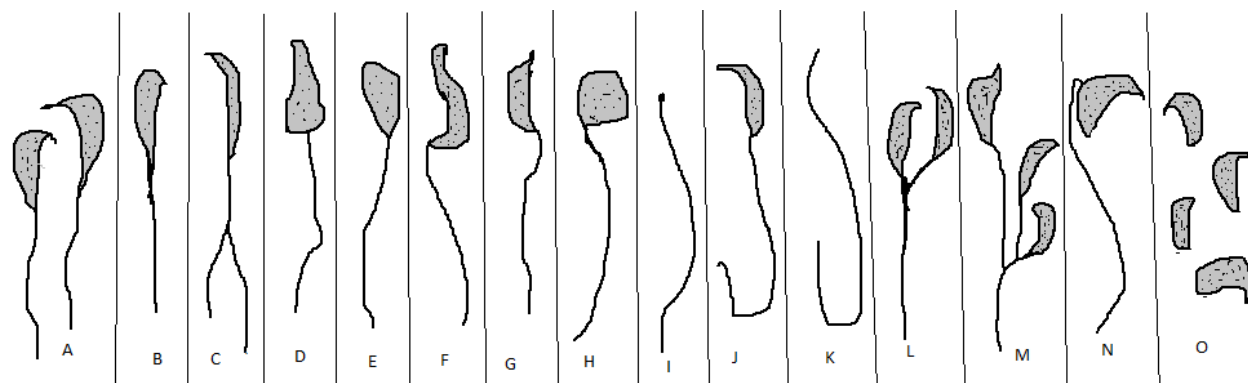


Figure 1. Observed shapes of normal and abnormal heads (A) normal sperm, (B) Sperm head with no hook, (C) Sperm cell with two tails, (D) Knobbed hook, (E) Amorphous head, (F) Bent hook, (G) Hook at wrong angle, (H) Tail folded over head, (I) Pin-head, (J) Banana shaped head, (K) Tail with no head, (L) Tail with two heads, (M) Tail with three heads, (N) Tail at wrong attachment, (O) Heads with no tail.

Table 1: Effects of the Oral Administration of the Ethanol Extract of *L. cupanioides* on the Weight of the Mice.

Treatment	Week 1	Week 2	Week 3	Week 4	Week 5	Week 6	Week 7
Control	22.0±0.71	20.2±0.46	20.3±0.73	20.5±1.04	20.6±1.13	20.8±1.11	21.4±1.09
100mg/kg	25.6±0.68 ^b	23.3±0.39	22.1±0.52	21.5±0.53	21.3±1.02	19.5±0.77	20.7±1.08
400mg/kg	25.1±0.62 ^b	22.7±0.57	21.4±0.66	20.5±0.64	20.1±0.71	20.5±0.58	21.9±1.30

Data presented as Mean ± SEM, where N=10 (a- P<0.05, b- P<0.01, c- P<0.001)

Table 2: Effects of the Ethanolic Extract of *L. cupanioides* on Sperm Formation.

Treatment	Total no. of sperm	Total no. of abnormal sperms	% of abnormal sperms	Total average of abnormal sperm head	% Difference from control	T ₂
CONTROL	2000	1293	21.55	92.36 ± 45.98		
100mg/kg	2000	1292	21.53	92.29 ± 28.23	-0.02	0.999
400mg/kg	2000	1332	22.20	95.14 ± 34.95	0.65	0.962
TOTAL	6000	3917	65.28	187.79 ± 109.16	0.63	1.961

Data represented as Mean±SEM (N=14). (a-P<0.05, b-P<0.01, c-P<0.001)

week of age of such mice (7). In this study, the weight of the treatment was not significantly at variance with the control.

Sperm abnormality test recorded the incidence of fourteen distinct types of sperm malformations. The major abnormalities found were sperm head with no hook, sperm tail with no head and sperm head with no tail.

Sperm Structure and Types of Abnormalities

Fourteen distinct types of sperm head abnormalities were observed in the mice during the *in vivo*

evaluation of the plant extract – *L. cupanioides*. These abnormalities included no hook (B), head with double tails (C), knobbed hook (D), amorphous head (E), bent hook (F), hook at wrong angle (G), tail folded over head (H), pin head (I), banana-shaped head (J), tail with no head (most prominent) (K), tail with double heads (L), head with triple tails (M), wrong tail attachment (N) and head with no tail (O). The tail with no head occurred prominently across the control and the group dozed with 400mL/kg, while the no hook occurred prominently in the group dozed with 100mg/kg.

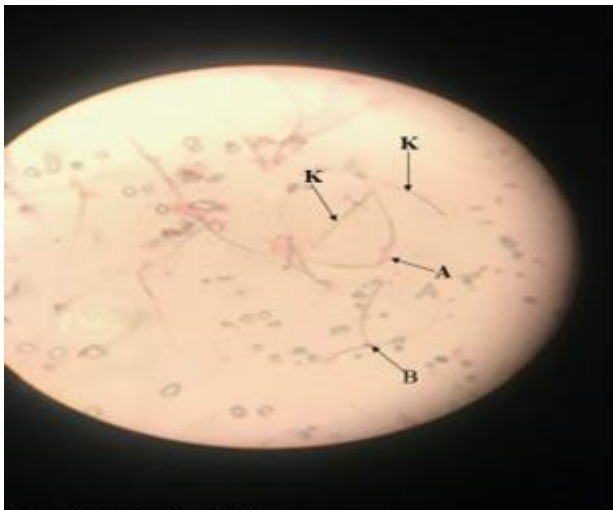


Fig 2a: Control X40

Fig. 2a (control) The sperm cell labelled A is a normal with hook, while B and K are abnormal sperm cells with no hook and headless tail respectively.

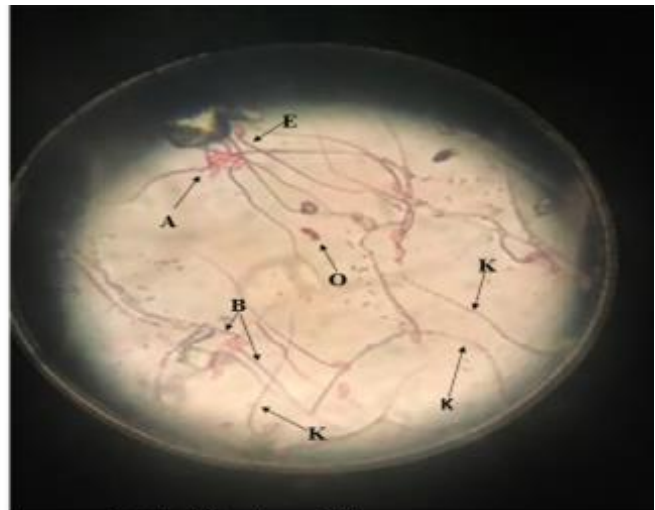


Fig 2b: 100mg/kg X40

Fig 2b: sperm cells in this experimental group appeared more abundant than the control and the 400mg/kg. The sperm cell labelled 'A' is normal with hook, 'B' is an abnormal with no hook, 'E' is an abnormal with amorphous head, 'K' are abnormal headless sperm cells and 'O' is an abnormal sperm head with no tail.

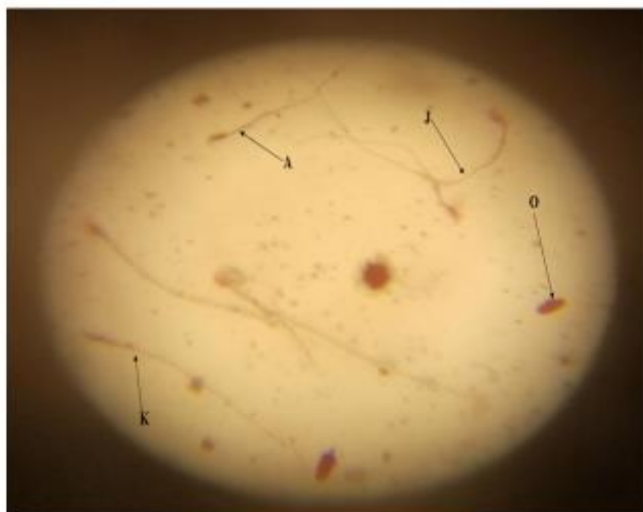

Fig 2c: 400mg/kg X40

Fig 2c: Sperm cells in this experimental group appeared scanty compared to the control and 100mg/kg. The sperm cell labelled 'A' is a normal sperm cell with hook, 'J' is an abnormal with banana-shaped head, 'K' is an abnormal with no head and 'O' is an abnormal with no tail.

Micrograph of Sperm Cells

A proportionately greater and consistently dominant incidence was observed for headless tail compared to all other varying types of sperm head abnormality in the treated mice as well as in the control. Higher incidence sperm malformation was observed in the highest dose (400mg/kg), though not significantly different from the control.

Sperm Head Aberrations

For this exposure, the total abnormality was 65.28% and this was insignificant at P level ($t=1.961$). The control value was 21.55%, which was greater than the group dozed with 100mL/kg and less than the group dozed with 400mg/kg.

It was cytologically observed that none of the groups induced any peculiar type of sperm abnormality, but

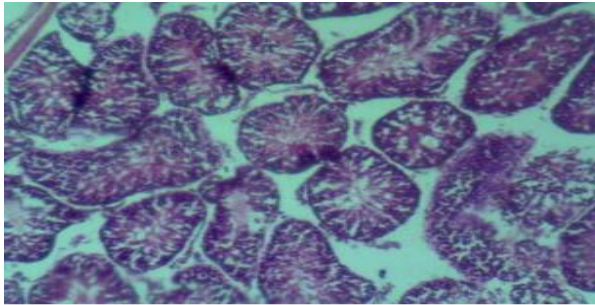


Fig. 3a: 100mg/kg

Fig 3a: shows the thick infolding of the tunica albuginea (a protective layer made of densely packed fibres that protect the testes). Sections of the testes shows unremarkable testicular architecture. No pathology is seen as all are normal testicular histoarchitecture.

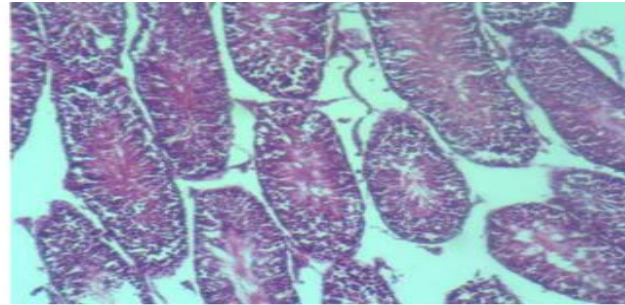
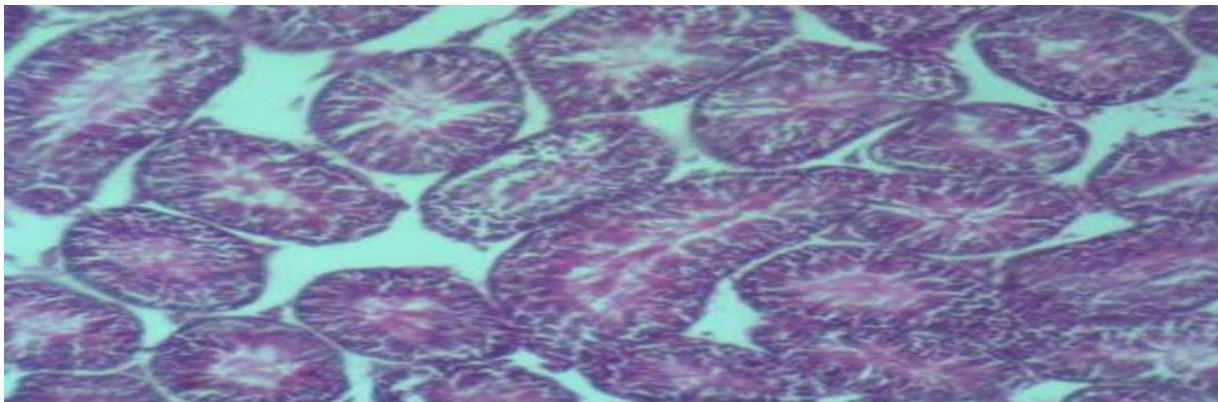


Fig. 3b: 400mg/kg

Fig 3b: shows the thick infolding of the tunica albuginea (a protective layer made of densely packed fibres that protect the testes). Sections of the testes shows unremarkable testicular architecture. No pathology is seen as all are normal testicular histoarchitecture.



Control (distilled water)

Fig 3c: shows the thick infolding of the tunica albuginea (a protective layer made of densely packed fibres that protect the testes). Sections of the testes shows unremarkable testicular architecture. No pathology is seen as all are normal testicular histoarchitecture.

rather a variety of abnormalities including the control. The abnormalities observed in the treatment groups were similar to the ones in the control. This implies that the extract might not be responsible for the morphologically abnormal sperms observed in the treatment groups. Hence, the damages might have occurred during pre-meiotic stages of spermatogenesis, because during spermatogenesis DNA synthesis occurs prior to the pre-meiotic phase of which no further DNA synthesis takes place during spermatogenesis in the cell cycle (8). It has been reported that variations in spermatozoa DNA content and obvious morphological alterations are often genetically controlled (8). Hence, various sperm abnormalities might probably be attributed to naturally occurring mistakes during the process of differentiation in spermiogenesis (8-10),

chromosomal aberrations which might occur while packaging of the genetic material in the sperm head (11), occurrence of small deletions and point mutation during spermatogenesis (12-16). Alterations in testicular DNA or genetic mechanism, which consequently disrupt the differentiation processes of spermatozoa, might also have resulted in some of the sperm abnormalities observed in this study (10).

Histologic evaluation also showed a conserved histoarchitecture of the testes in both the treatment and control, thereby, suggesting the safety of the ethanolic extract of *L. cupanioides* at doses investigated.

Histology of the Testes

Figures 3 a, b & c. Histology of 100,400mg/kg and the control group respectively, all showing thickness in folding of the tunica albuginea (a protective layer made of densely packed fibres that protect the testes).

Sections of the testes show unremarkable testicular architecture. No pathology is seen, as all are normal testicular histoarchitecture.

Conclusion

This study indicated that the ethanolic extract of *L. cupanioides* at 100mg/kg⁻² and 400mg/kg could not cause significant damages to the sperms and histology, which is indicative of the fact that the testes were conserved. The extract did not alter the male reproductive system at short time exposure of 49 days. Further studies are required to evaluate its chronic activities.

Acknowledgment

I hereby appreciate Mr. A. E. Adeshola for adequate care of the mice during the period of treatment in the animal house of the Department of Cell Biology and Genetics, University of Lagos.

Conflict of Interest

The authors declare that they have no conflict of interest.

References

1. Abe AI, Wakeel OK, Olapade M K. Bioassay-guided fractionation of antinociceptive effect of *Lecaniodiscus cupanioides* using mice. *European Journal of Pharmaceutical and Medical Research*. 2019;6(2):88-95.
2. Nafiu M, Abdulsalam T, Jimoh, R, Kazeem M. Ameliorative Effect of *Lecaniodiscus cupanioides* (Sapindaceae) Aqueous Root Extract in Loperamide-Induced Constipated Rats *Tropical Journal of Pharmaceutical Research*. 2015;14(6):1057-62.
3. Olaide NO, Ajiboye TO. Aqueous root extract of *Lecaniodiscus cupanioides* restores the alterations in testicular parameters of sexually impaired male rats *Asian Pacific Journal of Reproduction*. 2012;1(2):120-4.
4. Yemitan OK, Adeyemi OO. CNS depressant activity of *Lecaniodiscus cupanioides*, *Fitoterapia*. 2005;76(5):412-8.
5. Adeyemi OO, Yemitan OK, Adeogun OO. Analgesic activity of the aqueous root extract of *Lecaniodiscus cupanioides*. *West African Journal of Pharmacological and Drug Research*. 2004;20 (1-2):10-4.
6. Oloyede AM. The Reproductive Toxicity of the Ethanolic Extract of *Tetrapleura tetraptera* Pods on Male and Female Swiss Albino Mice (*Mus musculus*). *Herbal Medicines Journal*. 2018;3(1):1-7.
7. Otunbajo OA, Mosuro AA, Ladipo TF. An in vivo Evaluation of Induction of Abnormal Sperm Morphology by Invermectin MSD (Mectizan). *Pakistan Journal of Biological Sciences*. 2007;10(1):90-5.
8. Bakare AA, Adekunle A, Mosuro AA, Osibanjo O. An in vivo evaluation of induction of abnormal sperm morphology in mice by landfill leachates. *Mutation Research*. 2005;582:28-34.
9. Otitolaju AA, Obe IA, Adewale OA, Otubanjo OA, Osunkalu VO. Preliminary study on the induction of sperm head abnormalities in mice, *Mus musculus*, exposed to radiofrequency radiations from global system for mobile communication base stations. *Bulletin of Environmental Contamination Toxicology*. 2010;84:51-4.
10. Agunbiade SO, Okonko IO, Alimba CG, Folarin AC, Anugweje KC. Effects of a carbonaceous bottling plant effluent on albino mice sperm morphology and testes histopathology. *Natural Science*. 2012;10:154-60.
11. Rasgele PG. Abnormal sperm morphology in mouse germ cells after short – term exposures to acetamiprid, propineb, and their mixture. *Arh Hig Rada Toksikol*. 2014;65:47-56.
12. Narayana K, D'Souza UJ, Seetharama Rao KP. Ribavirin-induced sperm shape abnormalities in Wistar rat. *Mutation Research*. 2002;513:193-6.
13. Mendoza-Lujambio I, Burfeind P, Dixkens C, Meinhardt A, Hoyer-Fender S, Engel W, et al. The Hook1 gene is non-functional in the abnormal spermatozoon head shape (azh) mutant mouse. *Human Molecular Genetics*. 2002;11:1647-58 .
14. Pyle A, Handel MA. Meiosis in male PL/J mice: a genetic model for gametic aneuploidy. *Molecular Reproduction and Development*. 2003;64:471-81.
15. Escalier D, Bai XY, Silvius D, Xu PX, Xu, X. 2003. Spermatid nuclear and sperm periaxonemal anomalies in the Mouse Ube2b null mutant. *Molecular Reproduction and Development* 65:298-308.
16. Lamara AS, Fonseca G, Fuentes JL, Cozzi R, Cundari E, Fiore M, et al. Assessment of the genotoxic risk of *Punica granatum L.* (Punicaceae) whole fruit extracts. *Journal of Ethnopharmacology*. 2008;115:416-22.

© Oloyede Adeola Michael, Anyika Chidalu Christabel, Bodunrin Ottu. Originally published in the *Herbal Medicines Journal* (<http://www.hmj.lums.ac.ir>), 22.08.2020. This article is an open access article under the terms of Creative Commons Attribution License, (<https://creativecommons.org/licenses/by/4.0/>), the license permits unlimited use, distribution, and reproduction in any medium, provided the original work is properly cited in the *Herbal Medicines Journal*. The complete bibliographic information, a link to the original publication on <http://www.hmj.lums.ac.ir/>, as well as this copyright and license information must be included.